

Subsumption and Formation-Nevus cells Lymph Node

Anubha Bajaj

Histopathologist, Panjab University, India.

Corresponding Author: Anubha Bajaj, Histopathologist, Panjab University, India.

Received: March 29, 2026; **Published:** March 30, 2026

Nevus cells confined to lymph node parenchyma is a condition which commonly emerges within axillary lymph nodes and displays an incidence of up to 7%. The condition is prevalent within sentinel lymph nodes of subjects with malignant melanoma and appears concordant with cutaneous nevi or congenital cutaneous nevi (1,2).

Besides, the inclusions may represent as benign metastases arising from intradermal nevus confined within zones of concurrent lymphatic drainage (3,4).

Upon microscopy, singular cells, linear configuration or aggregates of miniature, spherical to elliptical nevus cells impregnated with moderate pale to clear cytoplasm, spherical nuclei with fine chromatin and indistinct nucleoli are observed (5,6).

Cellular or nuclear pleomorphism is absent. The cellular amalgamation is commonly confined within a distinct fibrous tissue capsule. Besides, cellular aggregates appear enmeshed within fibrous tissue trabeculae, nodal parenchyma or may circumscribe a miniature vascular articulation (7,8).

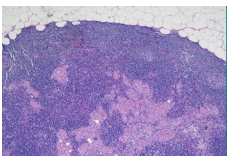


Figure 1: Nevus cell inclusions within lymph node parenchyma demonstrating singular cells and aggregates of nevus cells impregnated with moderate pale to clear cytoplasm, spherical nuclei with fine chromatin and indistinct nucleoli (16).

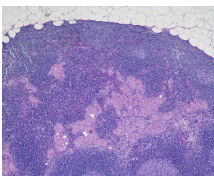


Figure 2: Nevus cell inclusions within lymph node parenchyma delineating singular cells and aggregates of nevus cells pervaded with moderate pale to clear cytoplasm, spherical nuclei with fine chromatin and indistinct nucleoli (17).

Breast tissue	Axillary
Aggregate of nevus cells	Axillary
Blue nevus	Axillary
Squamous epithelium	Cervical and peri-pancreatic
Salivary gland tissue	Cervical
Thyroid follicles	Cervical
Decidual tissue	Pelvic
Epithelium of paramesonephric type	Pelvic Intestinal glands Mesenteric
Mesothelial cells	Mediastinal and retroperitoneal

Table: Heterotopic inclusions confined within lymph nodes (9).

Nevus cells confined to lymph node appear immune reactive to S100 protein, MART1, tyrosinase or p16 (10,11).

Inclusion of nevus cells within lymph node parenchyma appear immune non reactive to human melanoma black 45 (HMB45) antigen.

Ki-67 proliferative index appears <1% (12,13).

Nevus cell inclusion within lymph node requires segregation from conditions as blue nevus, distant metastasis from carcinoma or malignant melanoma or Spitz nevus (14,15).

References

1. Valentini R, Quinn J, Murphy MJ (2025). Nevoid melanoma. *Clin Dermatol* 43:29–35.
2. Druskovich C, Kelley J, Aubrey J et al (2025). A review of melanoma subtypes: Genetic and treatment considerations. *J. Surg. Oncol* 131:356–364.
3. Hegedűs F, Ujfaludi Z, Oláh-Németh O et al (2025). Nevus with Intralymphatic Nevus Cell Protrusion and Lymphatic Invasion. *Diagnosics (Basel)*. 15(18):2382.

4. Wang LC, Tsai CC, Lin TC et al (2025). Current findings of genetic alterations and associated targeted therapies of conjunctival melanocytic neoplasms. *Taiwan J. Ophthalmol* 15:26–33.
5. P, Castrejon N, Marginet M et al (2024). Combined WNT-activated deep-penetrating/plexiform melanocytoma: Insights into clinicopathological and molecular characterization. *Clin. Exp. Dermatol* 49:356–363.
6. Ng S, Hall KC, Busam KJ et al (2024). Superficial Wnt-activated melanocytic nevi/melanocytomas with a junctional component: A case series. *Am. J. Dermatopathol* 46:648–652.
7. Ebbelaar CF, Schrader AMR, van Dijk M et al (2022). MOLEcular Evaluation of Melanocytic Ambiguous Tumors (MOLEMAT) Investigators Towards diagnostic criteria for malignant deep penetrating melanocytic tumors using single nucleotide polymorphism array and next-generation sequencing. *Mod. Pathol* b35:1110–1120.
8. Sood N, Mukherjee M (2018). Dermal lymphatic invasion: A rare feature in benign intradermal nevus. *Int. J. Appl. Basic Med. Res.* 8:253–255.
9. Spinardi JR, Goncalves IR D, La Falce TS et al. Benign inclusions in lymph nodes. *Int. J. Morphol.*, 25(3):625-629, 2007.
10. Koh SS, Roehmholdt BF, Cassarino DS (2018). Immunohistochemistry of p16 in nevi of pregnancy and nevoid melanomas. *J. Cutan. Pathol.* 45:891–896.
11. Leblebici C, Kelten C, Gurel MS et al (2016). Intralymphatic nevus cells in benign nevi. *Ann. Diagn. Pathol.* 25:1–6.
12. Kim HS, Lee SH, Moon HS et al (2014). Intradermal melanocytic nevus with lymphatic nevus cell embolus: A case report. *Oncol. Lett.* 7:331–333.
13. Kutzner H, Metzler G, Argenyi Z et al (2012). Histological and genetic evidence for a variant of superficial spreading melanoma composed predominantly of large nests. *Mod. Pathol* 25:838–845.
14. Ko CJ, Bologna JL, Glusac EJ (2011). ‘Clark/dysplastic’ nevi with florid fibroplasia associated with pseudomelanomatous features. *J. Am. Acad. Dermatol.* 64:346–351.
15. Fabrizi G, Pennacchia I, Pagliarello C et al (2008). Sclerosing nevus with pseudomelanomatous features. *J. Cutan. Pathol.* 35:995–1002.
16. Image 1 Courtesy: Libre Pathology
17. Image 2 Courtesy: Basic Medical Key