



Prevalence of Incidental Fundus and ocular abnormalities in Patients with Normal Best Corrected Visual Acuity at Makkah Eye Complex in Port Sudan, Sudan, 2022

Mohammad Al Zoubi¹, Mahgoub Saleem², Nada O. Ibrahim³

¹A Thesis Submitted in Partial Fulfillment of the Requirement for the Medical Doctorate in Ophthalmology (Clinical M.D)

²Professor of Ophthalmology MBBS, DORCS (Eng.), MRCOphth, FRCOphth, FACS, FICS, FICO

³MBBS, MS in Biomedical Sciences (USA), MD Ophthalmology, Neuro-Orbit trainee

Corresponding Author: Mohammad Al Zoubi, A Thesis Submitted in Partial Fulfillment of the Requirement for the Medical Doctorate in Ophthalmology (Clinical M.D).

Received: October 05, 2025; **Published:** October 24, 2025

Abstract

Background: Fundus and ocular abnormalities in people with normal or best visual acuity (BCVA) of 6/6 may be many and should not be ignored. The prevalence of non-vision impairing conditions (NVIC) is important from a public health perspective providing basis for effective national eye health screening policies and programs.

Objective: To determine the prevalence of Incidental Fundus and ocular abnormalities in Patients with Normal Best Corrected Visual Acuity.

Methodology: A retrospective cross-sectional hospital-based study was conducted at Makkah Eye Complex in Port Sudan city (PMEC); Red Sea state; Sudan. Data was collected from patients' records, covering the whole 428 seen patients in OPD was with normal; BCVA 6/6 vision, from January to December 2022, then analyzed by SPSS (28.0). Ethically cleared from Sudan Medical Specialization Board.

Results: Majority of patients: 385(90%) were \leq 40 years, with male gender dominance: 251 (58.6%): 177 (41.4%), [ratio: 1.4: 1]. The commonest cause for visiting the OPD was routine checkup; 392 (91.6%), and 28 (6.5%) for refraction.

Then trauma 4 (0.9%), post-surgery visit 2 (0.5%) and for foreign body 2 (0.5%). Some patients reported risk factors such as diabetes mellitus in 35 (8.2%) patients, Ageing in 23 (5.4%) and hypertension in 13 (3%). Slit Lamp adnexa and anterior segment findings: eye lid abnormalities was 7 (1.6%) patients, conjunctival lesions 19 (4.4%), corneal 13 (3%), scleral 5 (1.2%), abnormal AC in 3 (0.7%), iris disorders 4 (0.9%), then lens abnormalities only 3 (0.7%). Twelve (2.8%) patients with high intraocular pressure (IOP) $>$ 21 mm Hg. Retinal findings seen in 17 patients; the comments were: Optic nerve cupping in 5 (1.2%), Hypertensive changes in 4 (0.9%), salt and pepper 3 (0.7%), Papilledema 2 (0.5%). While Diabetic's changes, bone spicules, Retinal Detachment, each reported one case (0.2) each. Abnormal features in visual field reported in 5 (1.2%), B scan in 5 (1.2%) and OCT: 8 (1.9%) were detected. The commonest final diagnosis was glaucoma (2.6%), VKC (2.1%), Vitamin A deficiency (1.2%), high myopia (0.9%), pinguecula (0.7%), subconjunctival haemorrhage 2 (0.5%), xerophthalmia (2.2%), refractive error was 4.8%.

Conclusion: This study clearly identified reported incidents of vision-threatening abnormalities in some patients with normal or BCVA of 6/6. These findings ranged from external eye abnormalities to retinal abnormalities as well as high IOP. This signifies the importance of full ophthalmic examination to every patient attending the OPD even those with normal or BCVA of 6/6.

Keywords: Incidental, Fundus, BCVA, Slit Lamp, Adnexa, Glaucoma, Papilledema, VKC, B scan, OCT, Subconjunctival Haemorrhage, Xerophthalmia.

Introduction

The variation in prevalence of various ophthalmic health disorders is well known in many communities, [1, 2] possible due to differences of socio-environmental determinants of health and health inequalities. [3] The presence of asymptomatic ocular conditions is considerably high in elderly and children in developing countries, [1] which support the need of regular cost-effective eye screening programs to pick up who is at risk [4, 5] Diabetic Retinopathy (DR) Systematic screening programs which include educational campaigns to raise public DR awareness are popular good example of such policies. [1,6] The most significant findings of these policies may reveal that even a slight decrease in visual acuity can have detrimental effects on an individual's quality of life. They also noted that the increasing number of people with advanced age and ocular disorders is a contributing factor to the development of these conditions. [2]

The Incidental Fundus and ocular abnormalities in healthy individuals with good BCVA help in the recognition of conditions that reduce vision and have a serious impact in terms of later morbidity; like early non-syndromic retinitis pigmentosa which is one of the serious Incidental findings in children with normal vision. [7] Like these study may serve as a medium of public health message regarding future decreased vision from some silent etiological factors. [2] Children eye health is an important public health issue of global priority in low and middle-income countries, Sudan is not an exceptional; that needs well-integrated, innovative; strategies avoid delayed incidentally discovered series ocular abnormalities. [2] Therefore; many international organizations like International Agency for the Prevention of Blindness (IAPB) 2018 adopted standard school eye health screening guidelines for low and middle-income countries. [9, 10, 11] American Academy of Ophthalmology and the American Optometry Academy recommended early pediatric eye examination, while advanced age without any recognized risk factors should receive regular 1 to 3 years eye evaluation at age 40- >60, [12] to pick up many people presenting for an eye examination who are unaware that they have an eye disease.

1.2 Problem Statement

In developing countries the access to specialized ophthalmic care is not always possible. In Sudan, the economic and political upheavals last decades have led to the deterioration of the well-established National Health Services (NHS); that previously characterized the country, especially in the countryside. Therefore; patients with early stages of eye diseases face a substantial risk of progression that may lead to permanent loss of vision which may affect their quality of life and cost them a financial burden. As early detection and prompt management is at the top priority to prevent complications.

1.3. Justification:

To the best of our knowledge the concept of the prevalence of incidental fundus and ocular abnormalities in patients with normal best corrected visual acuity was not done in the country. However many patients may present late with poor vision. There for the research will provide general information about the possibilities of diagnosing and initiation of management as early stages of blinding diseases.

1.4. Research Questions:

What is the prevalence of Incidental Fundus and ocular abnormalities in Patients with Normal Best Corrected Visual Acuity at Makkah Eye Complex in Port Sudan?

1.5 Literature Review

Yadav S and Tamdo R emphasized on routine comprehensive eye examination because it presents a good opportunity to clarify the clinical picture and avoid missing the diagnosis. It helps to screen and diagnose common eye diseases, thus helping to reduce morbidity and the costs associated with eye diseases. A comprehensive eye examination is done when a patient with ocular symptoms seeks medical advice and also when a simple routine eye check-up is sought. [13]

Baranwal and fellows stated that the three most common causes of eye disorders were refractive error followed by allergic conjunctivitis and Presbyopia and they tend to present with normal or near normal visual acuity. They also concluded that the pattern of prevalence of various ocular diseases is likely to be similar to other parts of world for the same age group and with a similar occupational profile. [14]

In Brazil, Fernandes et al addressed the fundus and other ocular problems regardless of visual acuity status. In this study, a total 2384 eligible persons were enumerated and 2041 (85.6%) examined. The prevalence of ocular disturbances in either eye was 87.0% and was associated with male gender, older age, lower education, and rural residence. Overall, main findings were pterygium, cataract, and pinguecula, occurring in 58.8%, 45.4% and 17.4%, respectively. Among individuals with 20/20 VA in both eyes, the most frequent findings were pterygium, pinguecula, and glaucoma cupping, occurring in 47.4%, 31.2% and 6.5%, respectively. The high prevalence of ocular findings observed in this population reinforces that different conditions might not immediately decrease VA but can indicate risk and/or discomfort symptoms and should be considered when planning public health ophthalmic services. [15]

In United States, Ouyang et al addressed fundal and ocular abnormalities in screening of asymptomatic patients. In this study, a total of 284 eyes (144 subjects) were included, with a mean age of 38.1 years (range 18-77). Among 253 eyes (135 subjects) with gradable images from both FP and OCTs, the detection sensitivities for OCT were higher (96.2% in field and 85.7% in full field) than for FP (19.9% in field and 43.8% in full field) for all irregularities evaluated in the study (including epiretinal irregularities, abnormal retinal thickness, intraretinal hyperreflective/hyporefective features, and photoreceptor/RPE irregularities). Overall, the presence of definite irregularities on either fundus imaging or OCT by eye in this asymptomatic population was 42.6% (121/284), with 39.4% (112/284) of eyes having RPE irregularities such as drusen. They concluded that for detection of a variety of retinal irregularities evaluated in the current study, volume OCT scanning was more sensitive than nonmydriatic retinal photography in our asymptomatic individuals. OCT detected clinically relevant disease features, such as subretinal fluid, that were missed by FP, and had a lower upgradable image rate. It is likely that OCT will be added to photography screening in the near future for chorioretinal disease [16]

In Turkey, Sayin et al addressed the association of risk factors (diabetes) association with ocular and fundal findings. They stated that ocular complications associated with DM are progressive and rapidly becoming the world's most significant cause of morbidity and are preventable with early detection and timely treatment. This review provides an overview of five main ocular complications associated with DM, diabetic retinopathy and papillopathy, cataract, glaucoma, and ocular surface diseases. [17]

Moreover, Bruce et al addressed the association of risk factors (hypertension) association with ocular and fundal findings. Among 350 adult patients with asymptomatic eyes, forty-four patients (13.6%) in the FOTO-ED study had ocular fundus abnormalities relevant to ED care: 13 optic disc edema, 4 optic disc pallor, 4 retinal vascular occlusion, 13 isolated intraocular hemorrhages, and 10 grade III/IV hypertensive retinopathy.^[18]

Singh et al addressed the fundal, and ocular abnormalities that may associated with cancer. In this review, they stated that Cancer-associated retinopathy (CAR) is a rare retinal paraneoplastic disorder associated with cancer that can cause blindness. Investigations helpful in identifying this condition include visual fields, fundus autofluorescence (FAF), fundus fluorescein angiography (FFA), spectral-domain optical coherence tomography (SD-OCT), electrophysiological tests, and antibody testing. CAR is characterized by the presence of a hyper-autofluorescent parafoveal ring with normal autofluorescence within the ring and hypo auto fluorescence outside the ring primarily centered in the macular and peripapillary region. Hyper-auto fluorescent rings can also be seen in multiple disorders, including retinitis pigmentosa, X-linked retinoschisis, Leber congenital amaurosis, and cone dystrophy. In Retinitis Pigmentosa, a parafoveal ring of increased auto fluorescence (Robson-Holder ring) can be seen in up to 59 % of patients.^[19]

Objectives of the Study

1.6.1. General Objectives:

To study the Prevalence of Incidental Fundus and ocular abnormalities in Patients with Normal Best Corrected Visual Acuity at Makkah Eye Complex in Port Sudan, 2022.

1.6.2. Specific Objectives:

- To determine the different etiologies factors which may predispose the patients to fundus abnormalities.
- To determine the risk factors that may lead to progression of the disease and result in permanent loss of vision.

Materials and Methods

A retrospective, observational cross-sectional hospital-based study conducted in 428 Males and Females adults Sudanese patients who were seen in OPD clinics of Port Sudan Makkah Eye Complex (PMEC) in Port Sudan city, in a period of one year; January to December 2022. Data was extracted randomly from the patients' medical records through "Simple Random Selection" method for those patients with "Normal Vision or Best Corrected Visual Acuity (BCVA) of 6/6 at PMEC, during the study period. Sample size was calculated by a statistical sample size equation, keeping the Confidence Intervals Estimates being 95% and marginal error of 5% error.

Permission and ethical clearance was given prior to start from PMEC administration while ethical clearance was approved by Albasar institutional Research Board (IRB) from the Makkah Research Center (MRC) of Albasar International Foundation (BIF) at the Head Quarter in Khartoum; prior to start.

Port Sudan city is the capital of Red Sea State of Sudan and it is the main modern port of Republic of Sudan, which was built in 1905 to replace the old historic port of Suakin and 50 km north to it. The estimated recent population of Port Sudan city and its adjacent suburban areas is 775,228. Weather is hot-high-humid climate with extremely hot summers that exceed 45 °C (113 °F) temperatures and moderately hot

winters of 30 °C (86 °F). The city is hosting different Sudanese and non-Sudanese ethnic groups who are living side-by-side with the 5 Baja sub tribes (Hadendawa, Amara, Boshariaen, Beni-Amir, Halangha) original residents. PMEC is specialized ophthalmic hospital as one of the 9 hospitals of Albasar International Foundation (BIF) in Sudan. The complex consists of six consultants and specialists providing $\geq 60,000$ outpatient visits and 5,000 surgeries per year.

The data was collected by the researcher himself by reviewing all the 428 planed files out of the whole year 2022 patients' files; then reported in structured 'Data Collection Forms' which contained details about history, examination (Slit-Lamp exam), diagnosis, investigations (BCVA, IOP with Goldman, posterior segment examination, Ultrasonography (A/B scan), Optical Coherence Tomography (OCT) and Visual field if ordered to confirm the diagnosis) and follow-up visits.

2.2 Study Design

Retrospective, observational cross-sectional hospital-based study.

2.3. Study Period:

This study was conducted during the period from January to December 2022

2.4. Study Area:

The study was done in Port Sudan Makkah Eye Complex (PMEC) in Port Sudan city. It is the capital of Red Sea State of Sudan and it is the main modern port of Republic of Sudan, which was built in 1905 to replace the old historic port of Suakin and 50 km north to it. The city is hosting different Sudanese and non-Sudanese ethnic groups who are living side-by-side with the 5 Baja sub tribes. PMEC is specialized ophthalmic hospital as one of the 9 hospitals of Albasar International Foundation (BIF) in Sudan. The complex consists of six consultants and specialists providing $\geq 60,000$ outpatient visits and 5,000 surgeries per year.

2.5. Study Population:

The study was conducted on patients seen in the OPD clinic with a normal visual acuity or Best Corrected Visual acuity (BCVA) of 6/6, drawn from

2.6. Inclusion Criteria

- Adult patients aged \geq years or above.
- Sudanese nationality.
- Attended the OPD within the specified period.
- Normal Vision.
- BCVA of 6/6.

2.7. Exclusion Criteria

- Pediatric patients.
- Non-Sudanese patients.
- BCVA less than 6/6.

2.8. Sample Size And Technique

Data was extracted randomly from the patients' medical records through "Simple Random Selection" method for those patients with "Normal Vision or Best Corrected Visual Acuity (BCVA) of 6/6 at PMEC, during the study period. Complete ophthalmic examination, BCVA, slit-lamp exam, IOP with Goldman tonometry finishing by posterior segment

examination were done. B scan, OCT and Visual field was ordered when required. Sample size was calculated by a statistical sample size equation, keeping the Confidence Intervals Estimates being 95% and marginal error of 5% error.

2.9. Data Collection

The data was collected by the researcher himself by reviewing all the 428 planed files out of the whole year 2022 patients` files; then reported in structured `Data Collection Forms` (attached), which contained details about history, examination, diagnosis, investigations.

2.10. Variables:

2.10. 1. Independent:

- Age
- Gender
- Educational level,
- Residence

2.10. 1. Independent:

- Type and extent of fundus changes.
- Examination findings, Medical.
- Investigations.

2.11. Data Analysis

Data from the questionnaires were analyzed using the Statistical Package for Social Studies (SPSS 25) (Manufactured by IBM SPSS Inc. PASW Statistics for Windows, Version 28.0; 2009. Chicago: SPSS Inc., IL, USA), using parametric and non-parametric analysis methods. Categorical variables were analyzed using frequencies and percentage. Continuous variables were summarized using mean, percentile, range, and standard deviation. Significant differences and associations were determined by p values of less than 0.05 (P<0.05).

2.12. Data Presentation

The results were expressed in the form of simple tables and graphs (pie chart and bar chart) for each particular variable in the study objectives using the same (SPSS) software. Means and standard deviations were presented with relevant graphical representation for quantitative data. P. value of 0.05 or less is considered statistically significant

2.13. Ethical Consideration

Permission and ethical clearance was given prior to start from PMEC administration while ethical clearance was approved by Albasar institutional Research Board (IRB) from the Makkah Research Center (MRC) of Albasar International Foundation (BIF) at the Head Quarter in Khartoum; prior to start. The data collected was concealed ensuring participants' confidentiality.

Results

The current study covered 428 patients with normal visual acuity or Best Corrected Visual acuity (BCVA) of 6/6 in Port Sudan Makkah Eye Complex (PMEC) during the period from January to December 2022. The study found that the majority of the patients 385 (90%) were younger than 40 years in age, with male gender dominance 251 (58.6%) and male: female ratio of 1.4. The mean age was 35.8 ±15.35 (Range from17 to 55.5 years). [Table 1] [Figure 1, Figure 2]

Demographical characteristics	Frequency	Percent (%)	
Age groups in years	14 – 20 years	189	44.2%
	21 – 30 years	118	27.6%
	31 – 40 years	78	18.2%
	41 – 50 years	35	8.2%
	51 – 60 years	8	1.9%
Gender	Total	428	100 %
	Male	251	58.6%
Total	Female	177	41.4%
	Total	428	100 %

Table 1: Patients` Demographical Distribution (Age groups + Gender).

Note: BCVA: Best Corrected Visual Acuity. PMEC: Makkah Hospital Portsudan.

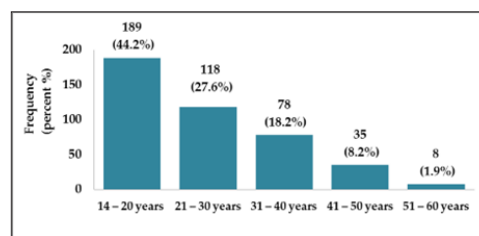


Figure 1: Age Groups Distribution.

Note: BCVA: Best Corrected Visual Acuity. PMEC: Makkah Hospital Portsudan

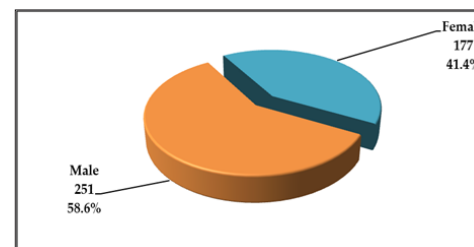


Figure 2: Gender Distribution.

Note: BCVA: Best Corrected Visual Acuity. PMEC: Makkah Hospital Portsudan

The most common cause for patients attending the OPD was for routine checkup 392 (91.6%), and refraction checkup 28 (6.5%). Four (0.9%) patients presented with trauma, 2 (0.5%) with post-surgery visit and 2 (0.5%) with foreign body. [Figure 3]

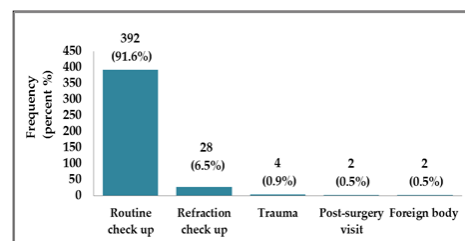


Figure 3: Patients Distribution according to their clinical presentation.

Note: BCVA: Best Corrected Visual Acuity. PMEC: Makkah Hospital Portsudan.

Some patients reported risk factors such as diabetes mellitus in 35 (8.2%) patients, aging in 23 (5.4%) and hypertension in 13 (3%) as detailed. [Table 2] [Figure 4]

	Clinical characteristics	Frequency	Percent (%)
Clinical presentation	Routine check up	392	91.6
	Refraction check up	28	6.5
	Trauma	4	0.9
	Post-surgery visit	2	0.5
	Foreign body	2	0.5
	Total	428	100.0
	Risk factors	Diabetes mellitus	35
Aging		23	5.4
Hypertension		13	3.0
Nothing		357	83.4
Total		428	100.0

Table 2: Clinical Characteristics and Risk factors Distribution.

Note: BCVA: Best Corrected Visual Acuity. PMEC: Makkah Hospital Portsudan

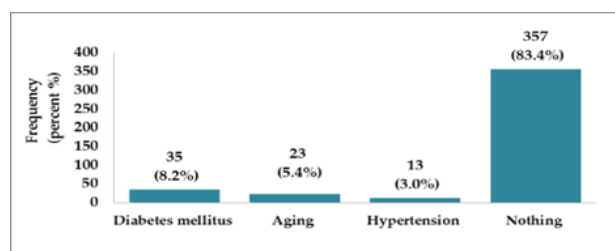


Figure 4: Patients Distribution according to their risk factors.

Note: BCVA: Best Corrected Visual Acuity. PMEC: Makkah Hospital Portsudan

Regarding the Slit Lamp Anterior Segment exam findings, the study found that eye lid abnormality was reported among 7 (1.6%) patients, conjunctiva among 19 (4.4%), 2 of which are Bitot's spots, cornea among 13 (3%), sclera among 5 (1.2%), AC among 3 (0.7%), iris among 4 (0.9%), and lens was reported among only 3 (0.7%) patients as detailed. [Table3] [Figure 5] The study found that 12 (2.8%) of the patients reported high intraocular pressure (> 21 mmHg). [Table 4] [Figure 6] The most common retinal examination findings were found among 10 (2.3%) patients as follow; hypertensive changes among 4 (0.9%), salt and pepper among 3 (0.7%), diabetic changes among 1 (0.2%), bone spicules among 1 (0.2%) and retinal detachment among 1 (0.2%). [Table 4] [Figure 7] Optic nerve cupping was reported only in 5 (2.2%) patients, and edema among 2 (0.5%). [Figure 8] Abnormal visual field was documented among 5 (1.2%) patients. [Figure 9] B scan among 5 (1.2%) as well and OCT among 8 (1.9%) as detailed. [Table 5]

In regards to the final diagnosis, 55 (12.9%) of the patients reported abnormal findings. The most common final diagnosis reported was glaucoma in 11 (2.6%) patients, VKC in 9 (2.1%), vitamin A deficiency in 5 (1.2%), myopia in 4 (0.9%), pinguecula in 3 (0.7%), and subconjunctival hemorrhage in 2 (0.5%), Episcleritis in 2 (0.5%), Pterygium in 2 (0.5%), Chalazion in 2 (0.5%), presbyopia in 2 (0.5%), posterior subcapsular cataract in 2 (0.5%), diabetic retinopathy in 1 (0.2%), Retinitis pigmentosa in 1 (0.2%), Conjunctival cyst in 1 (0.2%), hypertensive retinopathy in 1 (0.2%), Blepharitis in 1 (0.2%), trachoma in 1 (0.2%) and finally squint in 1 (0.2%) patient as shown. [Table 6] [Figure 7]

Slit lamp Anterior Segment Exam	Frequency	Percent (%)
Eye lid	Abnormal	7 1.6
	Normal	421 98.4
Conjunctiva	Abnormal	19 4.4
	Bitot's spots	2 0.5
Cornea	Normal	407 95.1
	Abnormal	13 3.0
Sclera	Normal	415 97.0
	Abnormal	5 1.2
AC	Normal	423 98.8
	Abnormal	3 0.7
Iris	Normal	425 99.3
	Abnormal	4 0.9
lens	Normal	424 99.1
	Abnormal	3 0.7
	Normal	425 99.3

Table 3: Slit Lamp Anterior Segment clinical findings Distribution.

Note: BCVA: Best Corrected Visual Acuity. PMEC: Makkah Hospital Portsudan.

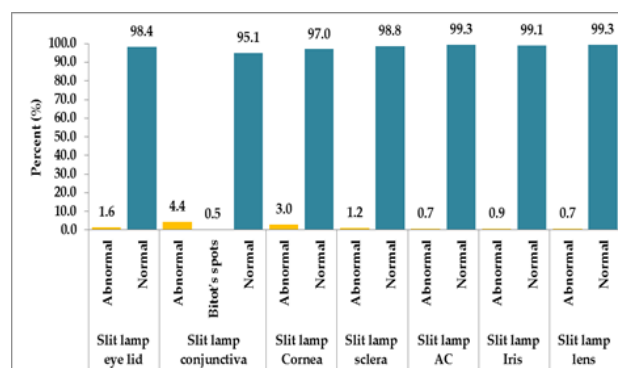


Figure 5: Slit Lamp Anterior Segment clinical findings Distribution.

Note: BCVA: Best Corrected Visual Acuity. PMEC: Makkah Hospital Portsudan .

Other findings	Frequency	Percent (%)
Intraocular pressure (IOP)	High	12 2.8
	Normal	416 97.2
Retina examination findings	HTN changes	4 0.9
	Salt and pepper	3 0.7
	DM changes	1 0.2
	Bone spicules	1 0.2
	Retinal Detachment	1 0.2
Normal	418 97.7	

Table 4: Intraocular pressure and Clinical Retina Findings Distributions

Note: BCVA: Best Corrected Visual Acuity. PMEC: Makkah Hospital Portsudan;

DM: Diabetes Miletus; HTN: Hypertension;

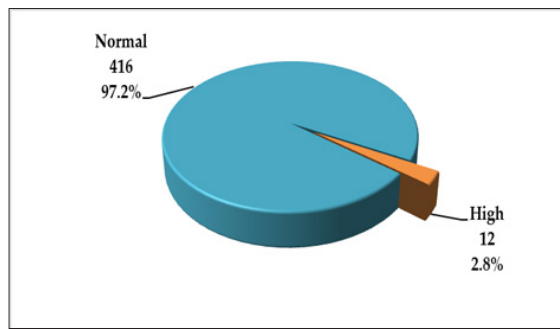


Figure 6: Distributions of Intraocular pressure.

Note: BCVA: Best Corrected Visual Acuity. PMEC: Makkah Hospital Portsudan

Other findings	Frequency	Percent (%)
Cupping	5	1.2
Optic nerve		
Edema	2	0.5
Normal	421	98.3
B scan		
Abnormal	5	1.2
Normal	423	98.8
OCT		
Normal	97	22.7
Abnormal	8	1.9
Not needed	323	75.4
Visual field if needed		
Abnormal	5	1.2
Normal	423	98.8

Table 5: Distribution of Other Eye Examination Findings

Note: BCVA: Best Corrected Visual Acuity. PMEC: Makkah Hospital Portsudan

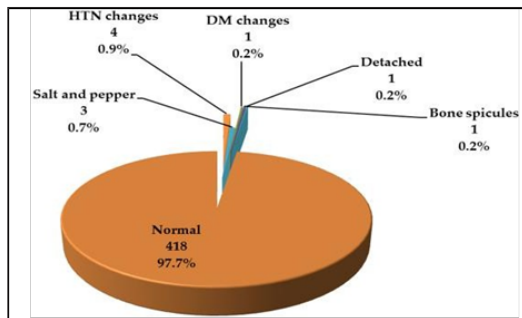


Figure 7: Distributions of Clinical Retina Findings.

Note: BCVA: Best Corrected Visual Acuity. PMEC: Makkah Hospital Portsudan.

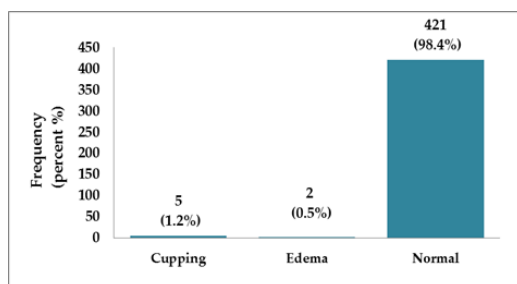


Figure 8: Distributions of patients According to optic nerve examination.

Ocular findings and final diagnosis	Frequency	Percent (%)
Presence of Ocular findings		
Abnormal	55	12.9
Normal	373	87.1
Diagnosis		
Glaucoma	11	2.6
VKC	9	2.1
Vitamin A deficiency	5	1.2
Myopia	4	0.9
Pinguecula	3	0.7
Subconj. haemorrhage	2	0.5
Episcleritis	2	0.5
Pterygium	2	0.5
Chalazion	2	0.5
Presbyopia	2	0.5
Posterior sub. cataract	2	0.5
DM retinopathy	1	1.1
Retinitis pigmentosa	1	0.2
Conjunctival cyst	1	0.2
HTN retinopathy	1	0.2
Blepharitis	1	0.2
Trachoma	1	0.2
Squint	1	0.2

Table 6: Distribution of Other Eye Examination Findings.

Note: BCVA: Best Corrected Visual Acuity. PMEC: Makkah Hospital Portsudan

VKC: Vernal Keratoconjunctivitis; DM: Diabetes Miletus; HTN: Hypertension; Subconj: Subconjunctival.

Discussion

The incidentally discovery of commonly occurring diseases are well known; ophthalmic eye disorders are not exceptional. [2] Hence detection of a significant number of fundus and other ocular abnormalities is routinely harvested [20] amongst people of different age groups presented to complementary routine exams in as pre-entry screening for schools, military services or any pre-employment processes etc. Their incidence and prevalence varies with the different socio-environmental status [2] providing basis of making good plans and decisions related to improve National Eye Health Service (NHS) and initiate proper programs for training health personnel stressing on non-vision impairing conditions (NVIC) common ocular conditions. [21]

Therefore, regular routine eye examinations help early identification of many serious incidental or any surprising serious ocular health problems, [22] both in rural or urban communities. Therefore, very important to activate the ophthalmic medical surveys on regular programs [23] funded by the competent authorities and those in charge of national eye health care, headed by the Ministry of Health and the state; as an effective strategy to address the late burden of visual impairment.

The current study aimed to assess the prevalence of incidental fundus and ocular abnormalities in 428 males and females Sudanese patients with normal vision and BCVA 6/6; at PMEC in Port Sudan, within the specified time frame; from January to December 2022.

It is noted that in our present study; the utmost majority of the targeted participants who were coming to ophthalmic OPD in PMEC during the study period was for periodic, routine or pre-employment eye checkup, constituting almost 91.6% of the study population. Certainly, it is a civilized behavior that people are proactively seeking medical check-up. The cause could be explained by the nature of the establishment of the city at the beginning of the last century as a modern port for Sudan. Wherein mixture of multiethnic residents and experts who work in many foreign companies, including Arabs, Asians' and Europeans; from all over the world. That time when the city called the 'Bride of the Red Sea' before the name was transferred to another; during the period of decay that permeated the country after glorious previous old days of prosperity. In another context this high percentage of (91.6%) indicated that many Sudanese adults in Port Sudan city coming to PMEC are highly utilizing the available facilities of eye care services. This high rate of utilization of the eye care services if compared with other studies in similar neighboring areas; like the study done in Hadassah city in South Ethiopia by Morka ED and colleagues (Hawassa city, South Ethiopia; 2016),^[24] where these researchers reported that 58.4% did not utilizing the available facilities of eye care services at all; as more than half of them claimed that they had no problem with their eyes. Still, it is higher than both Nigerian studies: 19% only of Southwestern Nigerian studies by Olusanya BA and group (Olusanya BA and co-workers 2016; Southwestern Nigeria)^[25] and the 23.8% of Abuja in Nigeria; by Ibeneche HO and group (Ibeneche HO; Abuja in Nigeria; 2018) utilizing the available facilities of eye care services.^[25]

The male gender dominance of the current study was up to 58.6%, which in general context it was in agreement with Summaya Khan and colleague's (86%) 'Rawalpindi-Pakistan's Study' in the year 2021.^[2] Furthermore, found in Nigeria study (64.2%) by Asaleye A and colleagues, where all had their male candidates more than female; with some few numerical variations.^[26] This predominance of males over females can be attributed to the delay of presentation in females to eye health services beside the inequitable access of females especially in rural areas like Eastern Sudan rather than gender bias.^[27, 28]

Although many studies concluded the association of fundal and ocular abnormalities such as glaucomatous cupping with male gender and older age,^{[29][30]} there is no consensus in the literature with studies indicating significant effects only on male gender,^[31] both gender^[32] or neither of them.^[31]

The mean age of the current study was 35.8 ± 15.35 from 17 to 55.5 years; which was younger by more than one decade than the mean-age of Khan's and colleagues; study, where their participants mean-age was 23.14 ± 5.66 years.^[2] The current study found that the majority of the patients (90%) were younger than 40 years in age, with male gender dominance (58.6%). Many studies;^[33, 34] agreed that recently, retinal problems seemed to develop more rapidly among younger individuals with some other comorbidities such as diabetes, and over 80% of those aged ≤ 60 years but with no gender differences in normal vision individuals.

The current survey; revealed only 12.9% of the participants showed some kind of fundus and ocular abnormal findings despite of the normal vision. Fundus findings constituting 2.3% patients: Optic nerve cupping being 1.2%; with suspicious of glaucoma. In the current study, some other participants reported risk factors such as diabetes Mellitus (DM) in 8.2% and hypertension in 3%.

Diabetes mellitus (DM) has been a global health burden due to its emerging epidemic challenging health systems in developing countries like Sudan. Prevalence of Diabetic Retinopathy (DR) 35.4% worldwide.^[35] Elwali ES and colleagues^[36] reported an overall frequency of DR

up 82.6% in patients attending retina clinic at Makkah Eye Complex (MEC) Khartoum; Sudan on the year 2017. This rate was higher than the older rate of 17.4% and 43%.^[36] So urgent strategies, investments and services to optimize the control and treatment of DM-HTN complexity is highly needed. Hypertensive Retinopathy (HR) changes seen as fundus findings seen in 0.9% of participants. Although the prevalence of hypertension itself in Sudanese patients with diabetes presenting to diabetes clinic was reaching 47.7%.^[37]

Apart from DR and HR; other fundal abnormal findings in patients with good vision consisting: Salt and pepper 0.7% and papilledema 0.5%. While bone spicules, retinal detachment, retinitis pigmentosa (RP) each reported 0.2%.

Papilledema was seen in 0.5% of our study population in spite of normal VA of 6/6; anyhow it is known that, opposed to many other types of optic neuropathy, visual acuity and color vision often remain normal in cases of papilledema until late in the course of disease.^[38]

Retinitis Pigmentosa (RP) with normal VA of 6/6 seen in one patient in this study (0.2%) could be attributed to rare cases of RP; like sector and pericentral RP which are usually stable, or with very slowly progressive^[39] usually discover as incidental fundal finding in patients coming only for routine checkup. Bone spicules (0.2%) seen as feature of RP. As well-known, peripheral retina bone spicules are pathognomonic feature of RP. Mottling and bone spicules and retinal detachment possible can be found in retinitis pigmentosa with good vision.^[40]

A previous study performed in the UK with over 3 million people attending eye health consultations showed that 88.1% of cases of fundal abnormalities were not associated with visual impairment complaint.^[41] Similar results observed in India and Kenya, with conditions not associated with decreased visual acuity accounting for 59% and 52%, respectively.^[42, 43]

Other adnexa and anterior segment (AS) ocular abnormal findings detected in this study were: VKC and Vitamin A deficiency in form of Bitot's spots both are generally similar to their typical pattern in other tropical countries. VKC was 2.1% and Vitamin A deficiency in form of Bitot's spots ranging from 1.2%-0.5%. In Gondar city, Northwest Ethiopia 2 studies presented a pit deferent results; VKC: 5.8%,^[44] Vitamin A deficiency in form of Bitot's spots 0.8% -1.2%.^[45] Apart from above more adnexa and anterior segment (AS) ocular abnormal findings were also seen: like Pinguecula (0.7%), Pterygium (0.5%), Subconjunctival haemorrhage (0.5%), Episcleritis (0.5%), Chalazion (0.5%), Conjunctival cyst, Blepharitis and trachoma from 0.2% to 0.7%.

Globally, Pinguecula is far more common than pterygium. The current study reflected this observation; as Pinguecula (0.7%) VS Pterygium (0.5%). Both; Pinguecula and pterygium varies in different environmental conditions. They are associated with outdoors occupational activity where people exposed to ultraviolet radiation.^[46] Alcohol consumption is strongly associated with pinguecula. Both disorders increase with age and are associated with outer activity.^[46] Incidence of non-traumatic subconjunctival hemorrhage in an Indian rural population was 0.3%,^[47] and 16.4% in Tunisian patients^[48] therefore are in contrary with the 0.5% which reported in the current study. Homayounfar G and colleagues reported in their "Pacific Ocular Inflammation Study" an overall incidence rates of Episcleritis to be 0.02% in Hawaiian population. Which was lower and not in alignment with the current study (0.5%).^[49]

In contrary to our 0.5% prevalence of Chalazion in our study; Patel S and associates in 2022 outlined a high prevalence of Chalazion in US older veteran population up to 6.04%.^[50] To some extent; Das AV and Dave TV in the Indian "Multi-Tier Eye Care Network in India: An Electronic Medical Records Driven Big" research reported the prevalence

of Chalazion could reach 0.95%.^[51] The low prevalence of Blepharitis and trachoma (0.2%) was observed during the current study. It is present at levels that are unlikely to be the dominant driving force for *Trachoma Follicular infection* (TF) in the population.^[52] This is supported by a long history of hard work to eradicate Trachoma as a Public Health Problem by the active “Sudan Trachoma Control Program” in many Localities in Eastern Sudan; some of those localities were in Sawakin^[53] (The historic port of Sudan near the city of Port Sudan).

Globally, cataract is a significant cause of reversible visual impairment.^[54] In the current study when included those with reasonably near-normal vision^[55] of ‘6/6.7 up to < 6/12’, cataract associated with ‘unmet need for cataract surgery’ (UNCS) we detected its prevalence to be 0.7%; as an incidental finding. In contrary; Richter GM and colleagues in Los Angeles Latino Eye Study^[56] reported a high percentage up to 34.3% of UNCS according to “Lens Opacities Classification System III (LOCS III).”^[57]

Refractive error (RE) is one of the commonest vision impairment; worldwide may range from 33.4% to 47%, in developing and developed countries respectively.^[58, 59] In our work we reported RE of 0.5% to 0.9%, mainly Myopia and Presbyopia. Ali AB and colleagues^[60] found myopia is more in Sudanese than other type of REs. However, Presbyopia (0.5%) as age-related REs, so definitely could be detected in our 40-60 year older group.

In similar context, studies agreed that the occurrence of non-vision impairing conditions (NVIC) is important from a public health perspective providing basis of making decisions related to training health personnel about common ocular conditions.^[21] Abayo G and co-researchers reported 25.8% prevalence and pattern of ocular morbidity among School Children in Southern Ethiopia (2021),^[61] mainly trachoma-related conditions (10.9%). VKC found to be 6.3%, refractive error was 4.8% and xerophthalmia in 2.2%. This higher results may due to their younger population mean age; < 16 years compared to > 36 years.^[61]

Fernandes and colleagues (2021);^[21] in the Brazilian Amazon Region study, reported a prevalence of ocular abnormality of 39.8% (37.7–42.0%) among individuals with 6/6 vision in both eyes. The most frequent ocular findings were pterygium (47.44%), pinguecula (31.16%) and glaucomatous cupping (6.51%).^[21] Kimani and co-searches (Mbeere District, Kenya; 2013)^[62] reported that in terms of posterior segment, glaucomatous cupping was the most observed finding and increased^[63] intraocular pressure is less frequent.^[62] Hussain Arif and group (2005) in Pakistan (Chakwal district) found prevalence of NVIC to be 14.6% when excluding presbyopia.^[63]

In that same context, Burton and colleagues (2021)^[42] reported the need for further eye consultation in such conditions with the potential of causing visual impairment as glaucomatous cupping and diabetic retinopathy and also conditions that are symptomatic but not likely to decrease visual acuity as conjunctival disorders.

Regarding the incidental glaucoma findings were 2.8% high intraocular pressure (IOP), 1.2% cupped discs and 1.2% with abnormal visual field. However frank glaucoma diagnosis reported in the study was 2.6%. It is known that high IOP may be an important factor in early discovering patients with glaucoma or at least glaucoma suspects.^[64] Although, combined clinical findings of high IOP, abnormal visual field and cupped discs all together are strongly predictive values to diagnose glaucoma,^[65] both are important long-term predictive values of the need to pick up patients referred or incidentally discovered to have glaucoma. In Malmö, Sweden, using IOP alone as the primary referral criterions for comprehensive eye examination.^[64] The study findings can be in similar

in context to many other studies concerning prevalence of glaucoma in Sudan or globally; such as the result of Zoelfig Abdurrahman’s thesis that submitted for M.sc Degree in Optometry and Visual Sciences; in Al Neelain university, Khartoum where he reported the prevalence of glaucoma in North Kordofan State was 2.22%.^[66] Almost in line with the worldwide reported prevalence of World Health Organization (WHO) prevalence of glaucoma with a global prevalence of 1.96%: (Africa 4.26%, Japan 3.31%, Latin America 3.16%, Europe 1.97%, India 1.75%, Middle East 1.31%, and SA Asia 1.31%, Saudi Arabia 5.6%,^[67] and Qatar 1.71%).^[68] Although very odd Sudanese glaucoma studies reported exaggerated prevalence rate; like Ali AB and colleague’s survey (Ali AB, Sudan 2022) who reported glaucoma prevalence rate of 17%, in White Nile State,^[60] and Mohammed MA, Haj HM hospital-based Study at Atbara, River Nile state, Sudan in the years 2009-2016 that reported 14.02% as the prevalence glaucoma.^[69] While Binnawi K and co-researchers demonstrated that Glaucoma responsible from 20% of the causes of blindness and visual impairment in population aged 50 years of North Kordofan State.^[70] No clear explanation of these high percentages, we hope a country-based study should be done soon. Also Samy El Gendy and Abdel-Kader highlighted the accidentally discovered high percentage of glaucoma (13.3%) and ocular hypertension (8.3%) in Sudanese patients coming to Egypt and subjected to first-time screening by the above two Egyptian ophthalmologists.^[71] It is clear that these large differences in results could be due to another scenario where those selected seen patients in Egypt were from a group originally diagnosed in Sudan with glaucoma and later went to seek further treatment or confirmation of the diagnoses in Egypt.

All incidental clinical eye examination findings in the current survey; adnexa, anterior segment (AS), posterior segment (PS), refraction were etc.; about 12.9% in total. Out of them Refractive errors (6.5%) being on the top. Next was corneal finding (3.0%), 2.6% glaucoma. Vernal Keratoconjunctivitis (VKC) was 2.1%. However all other examination findings or procedures were of low percentages; 0.2% to 1.2%. These incidental finding generally in line with Khan’s and colleagues study finding in Rawalpindi of Pakistan; 2021.^[2] Except in some other findings: like amblyopia 24.6%, strabismus 10%, cataract 7.3%, Macular scar 6.5% and color vision deficiencies 5.5% which were not detected in the our current study.

Incidental abnormal B scan (1.2%) and OCT 8 (1.9%) were detected, which may be supported by many other studies in the literature. As some incidental fundus findings could be detected by High-resolution OCT imaging^[72, 73] or *B-scan* ultrasonography,^[74] especially in Morphological Macular Abnormalities (MMAs) and vitreous degenerations; like foveal hypoplasia^[75] that by foveal were not detected by conventional imaging methods; or by Posterior Vitreous Detachment in spite of good vision.^[76]

The current study found that the majority of the patients (90%) were younger than 40 years in age, with male gender dominance (58.6%). Although many studies concluded the association of fundal and ocular abnormalities such as glaucomatous cupping with male gender and older age,^{[29] [30]} there is no consensus in the literature with studies indicating significant effects only on male gender,^[31] both^[32] and neither.^[31] In addition, other studies^[77] agreed that recently, retinal problems seemed to develop more rapidly among younger individuals with some other comorbidities such as diabetes, and over 80% of those aged ≤ 60 years but with no gender differences in normal vision individuals.

Although this study is dealing with patients with normal or BCVA of 6/6, it is noticed that the younger the patients the more complaint they present with, teenagers being the predominant age group (44.2%). This

might be due to many causes like excessive media use including cell phones, computers etc.).^[78] The complaint is noticed to be less with increasing age, reaching its lowest among the 6th decade group (1.9%). This might be due to older people are more genuine in visiting the OPD than younger group.

The study had some limitations, as all patients in the study are from one hospital in one state, which may affect the ability of the study results to be generalized.

Conclusion

This study clearly identified reported incidents of vision-threatening abnormalities in some patients with normal or BCVA of 6/6. These findings ranged from external eye abnormalities to retinal abnormalities as well as high IOP. This signifies the importance of full ophthalmic examination to every patient attending the OPD even those with normal or BCVA of 6/6.

Recommendations

1. Healthcare authorities and policy makers should evaluate ocular data beyond the visual acuity in order to provide access and proper facilities to guarantee the best ocular health for the population.
2. Further studies are highly recommended to evaluate the impact of screening service - programs in early recognition - detection of incidental fundus - ocular findings in patients with normal visual acuity.
3. We recommend another Research to be done in young age group (14-20 years old) for causes like phoria and excessive media use including cell phones, computers etc.

References

1. Michaud L, Forcier P. (2014) "Prevalence of asymptomatic ocular conditions in subjects with refractive-based symptoms". *J Optom.* Jul-Sep; 7(3):pp153-60
2. Khan S, Rafique A, Zafar O. (2021) "Frequency of incidental ocular findings during pre-employment screening at a tertiary care Eye hospital". *Pak J Med Sci.* May-Jun; 37(3):746-750.
3. World Health Organization (WHO). (2012) "Social and environmental determinants of health and health inequalities in Europe: fact sheet. European Health for All database [online database]. Copenhagen", WHO Regional Office for Europe.
4. Katibeh M et al; (2019) "Designing a Screening Program for Prevention of Avoidable Blindness in Iran through a Participatory Action Approach". *J Ophthalmic Vis Res.* Jan-Mar; 14(1):52-61.
5. Coney JM. (2019) "Addressing unmet needs in diabetic retinopathy". *Am J Manag Care.* Oct; 25(16 Suppl):S311-S316.
6. Ghanchi F; (2013) "Diabetic Retinopathy Guidelines Working Group. The Royal College of Ophthalmologists' clinical guidelines for diabetic retinopathy: a summary". *Eye (Lond).* Feb; 27(2):285-7.
7. Verbakel SV, et al; (2018) "Non-syndromic retinitis pigmentosa, Progress in Retinal and Eye Research", Volume 66, Sept, pp157-186
8. Sharma IP. (2021) "The Pediatric Eye Health Challenge Beyond 2020". *Am J Trop Med Hyg?* Jul 12; 105(3):555-556.

9. IAPB School Eye Health Work Group. (2018) "International Agency for the Prevention of Blindness (IAPB) Standard school eye health guidelines for low and middle-income countries"
10. Delpero WT, et al; (2019) "Evidence-based clinical practice guidelines for the periodic eye examination in children aged 05 years in Canada". *CAN J Ophthalmol*; (54) 6, Dec; pp751-758.
11. Bachani D. (2017) "School eye health in South Asia". *Community Eye Health*; 30(98):S1-S2.
12. American Academy of Ophthalmology (AAO) Preferred Practice Patterns Committee. Preferred Practice Pattern® Guidelines. (2014) "Comprehensive Adult Medical Eye Evaluation. San Francisco, CA" American Academy of Ophthalmology; 2010.
13. Yadav S, Tandon R. (2019) "Comprehensive eye examination: what does it mean?" *Community Eye Health*; 32(107):S1-S4.
14. Whitfield R, Schwab L, et al; (1990) "Blindness and eye disease in Kenya: Ocular status survey results from the Kenya Rural Blindness Prevention Project". *Br. J. Ophthalmol*; 74:333-340.
15. Zerihun N, Mabey D. (1997) "Blindness and low vision in Jimma Zone, Ethiopia: Results of a population-based survey". *Ophthalmic Epidemiol*; 4:pp19-26.
16. Singh MM, Murthy GV, et al; (1997) "A study of ocular morbidity among elderly population in a rural area of central India". *Indian J Ophthalmol*; 45: pp61-65.
17. Okoye O, Umeh RE, Ezepe FU. et al; (2013) "Prevalence of eye diseases among school children in a rural south-eastern Nigerian community". *Rural and Remote Health*; 13: 2357.
18. Holden BA, et al; (2008) "Global Vision Impairment Due to Uncorrected Presbyopia". *Arch Ophthalmol*; 126(12):1731-1739.
19. Yared AW, Belaynew WT, et al; (2012) "Prevalence of Refractive Errors Among School Children in Gondar Town, Northwest Ethiopia". *Middle East Afr J Ophthalmol*; 19(4):372-376.
20. Dobbeltstein D, (2015) "What percentage of patients presenting for routine eye examinations require referral for secondary care? A study of referrals from optometrists to ophthalmologists". *Clin Exp Optom.* May; 98(3):214-7.
21. Fernandes A, Berezovsky A, et al; (2021) "Prevalence of ocular findings regardless of visual acuity status in older adults from the Brazilian Amazon Region". *Sci Rep* 11,23710.
22. Mukamal R. 20 (2022) "Surprising Health Problems an Eye Exam Can Catch. American Academy of Ophthalmology". Reviewed by Taylor RJ, MD in Apr. 29.
23. Mafwiri MM, et al; (2016) "Mixed methods evaluation of a primary eye care training programme for primary health workers in Morogoro Tanzania". *BMC Nurs* 15, 41.
24. Morka ED, Yibekal BT, Tegegne MM et al: (2020) "Eye care service utilization and associated factors among older adults in Hawassa city, South Ethiopia". *PLoS ONE* 15(4): e0231616.
25. Olusanya BA, et al; (2016) "Determinants of utilization of eye care services in a rural adult population of a developing country". *Middle East African journal of ophthalmology*; 23(1):96.
26. Asaleye A, Olatunji RO, et al; (2016) "Ocular Ultrasonography in Ile Ife: incidental findings in the apparently normal eye and the implications for ocular health". *West African Journal of Ultrasound Vol* 17

27. Miani C, Wandschneider L, et al; (2021) "Measurement of gender as a social determinant of health in epidemiology—A scoping review". *PLoS ONE* 16(11): e0259223.
28. Aldrich MC, Cust AE, Raynes-Greenow C et al; (2019) "International Network for Epidemiology in Policy. Gender equity in epidemiology: a policy brief". *Ann Epidemiol.* Jul; 35:1-3.
29. Al-Tamimi ER. (2016) "Age, gender and refractive error association with intraocular pressure in healthy Saudi participants: A cross-sectional study". *Saudi J Ophthalmol.* Jan-Mar; 30(1):44-8.
30. Robinson B. (2003) "Prevalence of Asymptomatic Eye Disease Prevalence des maladies oculaires asymptomatiques"
31. Shin J, Kang MS, et al; (2020) "Association between metabolic risk factors and optic disc cupping identified by deep learning method". *PLoS One.* Sep 17;15(9):e0239071.
32. Pilat AV, Gottlob I, et al; (2014) "Gender- and ethnicity-related differences in optic nerve head topography in healthy Indian and Caucasian participants". *Neuroophthalmology*; 38:205– 212.
33. Lake AJ, et al; (2018) "J. A tailored intervention to promote uptake of retinal screening among young adults with type 2 diabetes - an intervention mapping approach". *BMC Health Serv Res* 18, 396.
34. Zhong ZL, Han M, Chen S. (2011) "Risk factors associated with retinal neovascularization of diabetic retinopathy in type 2 diabetes mellitus". *Int J Ophthalmol*; 4(2):182-5.
35. Kenneth Lado Sube, et al; (2020) "Diabetic Retinopathy and the Risk Factors in South Sudan: A Six Months Study", *International Journal of Clinical and Experimental Medical Sciences.* Volume 6, Issue 4, July, pp. 79-84.
36. Elwali ES, Almobarak AO, et al; (2017) "Frequency of diabetic retinopathy and associated risk factors in Khartoum, Sudan: population based study". *Int J Ophthalmol.* Jun 18; 10(6):948-954.
37. Almobarak AO, Badi S , et al; (2020) "The prevalence and risk factors for systemic hypertension among Sudanese patients with diabetes mellitus: A survey in diabetes healthcare facility: A survey in diabetes healthcare facility; *Diabetes & Metabolic Syndrome*" *Clinical Research & Reviews*, Volume 14, Issue 6, ,1607-1611.
38. McCafferty B, McClelland CM, Lee MS. Et al: (2017) "The diagnostic challenge of evaluating papilledema in the pediatric patient". *Taiwan J Ophthalmol.* Jan-Mar; 7(1):15-21.
39. Ballios BG, et al; (2021) "Beyond Sector Retinitis Pigmentosa: Expanding the Phenotype and Natural History of the Rhodopsin Gene Codon 106 Mutation (Gly-to-Arg) in Autosomal Dominant Retinitis Pigmentosa". *Genes (Basel).* Nov 23; 12(12):1853.
40. Jaissle GB, May CA, et al; (2010) "Bone spicule pigment formation in retinitis pigmentosa: insights from a mouse model". *Graefes Arch Clin Exp Ophthalmol.* Aug; 248(8):1063-70.